DIABETIC RETINOPATHY (DR):

Definition, Stages, Assessment & Treatment

REGENERON
SCIENCE TO MEDICINE®

WHAT IS DR?

Diabetic retinopathy (DR) is a progressive disease that occurs in patients with diabetes and is characterized by damage to the blood vessels in the retina, a thin layer of light-sensitive tissue at the back of the eye that helps the brain form images. DR is often caused by poor blood sugar control and may progress without any warning signs or symptoms in its early stages.[1-3]

As DR becomes more severe, the blood vessels in the retina can become increasingly weak and leak fluid. As blood vessels weaken, small new blood vessels may form. These blood vessels are also weak and may leak fluid as well. As the disease advances, the buildup and leakage of fluid from the weakened blood vessels can interfere with the normal functioning of the eye, causing vision loss that may worsen over time.[1, 2]

Serious, potentially vision-threatening events associated with DR may include: [1, 4]

- **Anterior segment neovascularization (ASNV)**, in which the development of abnormal blood vessels in the anterior segment (front) of the eye can lead to an elevation of intraocular pressure and vision loss.
- **Proliferative DR (PDR)**, the more advanced form of DR, during which fragile blood vessels can begin to grow in the retina. These new blood vessels may leak blood into the vitreous, the gel-like substance filling the eye, which can affect vision.
- **Center-involved diabetic macular edema (CI-DME)**, a complication of DR that can occur at any stage of the disease and refers to swelling of the macula, the central portion of the retina, due to leakage from retinal blood vessels.[5] DME may cause blurriness of vision and blind spots, make straight lines look wavy and/or make bright colors look dull or washed out.

HOW COMMON IS DR AND WHO IS AT RISK?

- It is estimated that about 30 million Americans have diabetes. Of these people, about **8 million have DR**,[6,7] and this number is expected to **increase to more than 14 million by 2050.**[7]
- **DR is the leading cause of blindness** among people with diabetes between the ages of 20 and 74 years.[8-10]
- **Factors that may increase the risk of DR** are having diabetes for a long time, uncontrolled or poorly controlled blood sugar, and high blood pressure. Other risk factors include African-American race, Hispanic ethnicity and pregnancy.[1,11]

APPROXIMATELY 8 MILLION OF THE 30 MILLION AMERICANS WITH DIABETES HAVE DR[7]

WHAT ARE THE STAGES OF DR?

DR is a progressive disease, with several stages[1]:

Non-proliferative DR (NPDR):
This is the first stage of DR. NPDR may be categorized as mild, moderate, moderately severe and severe. In many mild cases of the disease, there may be no warning signs or symptoms.

Proliferative DR (PDR):
Left untreated, NPDR can progress to PDR, the stage during which abnormal, fragile blood vessels grow on the surface of the retina and can leak and bleed into the eye. PDR is classified as mild, moderate or high risk.

HOW IS DR TREATED?

The goal of treatment for DR is to help slow progression of the disease before it threatens vision or results in serious vision loss.[12]

- It is important to manage the underlying diabetes, maintain a good diet, exercise, control blood pressure, avoid alcohol and tobacco use and schedule regular comprehensive eye exams.[1]
- Medical treatment options include laser therapy, to seal leaking blood vessels, and anti-VEGF (vascular endothelial growth factor) injections, which block a protein (VEGF) that can stimulate abnormal blood vessel growth and leakage.[5,13]

WHAT IS THE DIABETIC RETINOPATHY SEVERITY SCALE (DRSS)?

The Diabetic Retinopathy Severity Scale (DRSS) is a formalized way to "score" the severity of DR. It is commonly used in clinical trials to evaluate the efficacy of an investigational treatment by observing its ability to improve a trial participant's DRSS score over time.[14,15] Physicians may or may not assess DR using DRSS scores in real-world practice.

How the DRSS is used:

- The DRSS is based on observed damage to the retina seen in high-resolution pictures, as shown in the table. These observations are inputted into an algorithm, which determines the DRSS score.
- The more extensive the damage observed in the retina, generally the more severe the DR and the higher the DRSS score assigned.
- Reversal of DR progression is often characterized as step improvements in DRSS. For instance, if a patient's DRSS score improves from 47 to 43, this is considered a one-step improvement. Similarly, an improvement in score from 47 to 35 would be considered a two-step improvement.

DIABETIC RETINOPATHY SEVERITY SCALE (DRSS)

REPRESENTATIVE PHOTO*	DAMAGE TO THE RETINA OBSERVED	DRSS SCORE	CORRESPONDING DR STAGE
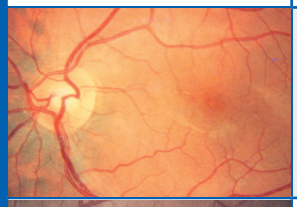	Absence of microaneurysms or other characteristics	10	**DR absent**
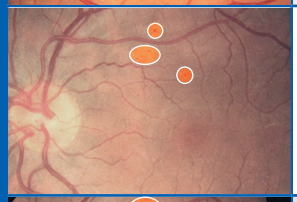	Microaneurysms only; other characteristics absent	20	**Microaneurysms only**
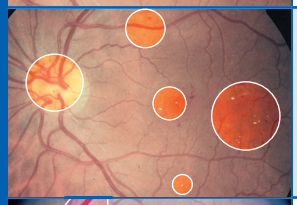	One or more: venous loops, hard exudates, soft exudates, retinal hemorrhages; other characteristics questionable or absent	35	**Mild NPDR**
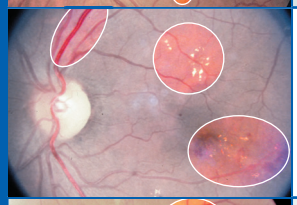	More extensive hemorrhages and microaneurysms than Mild NPDR, OR definite intra-retinal microvascular abnormalities (IRMA)	43	**Moderate NPDR**
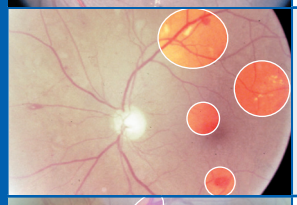	Both Moderate NPDR characteristics plus more extensive IRMA, more severe hemorrhages and microaneurysms, or definite venous beading	47	**Moderately Severe NPDR**
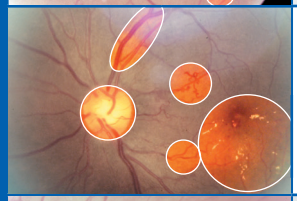	More extensive characteristics than moderately severe NPDR but without neovascularization of disc or retina	53	**Severe NPDR**
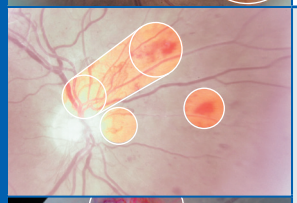	PDR is characterized by neovascularization of the disc and/or retina, vitreous hemorrhage, preretinal hemorrhage, which become more severe as levels advance	60, 61	**Mild PDR**
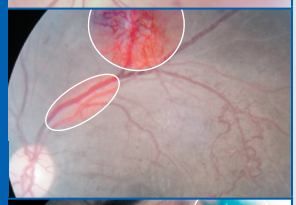		65	**Moderate PDR**
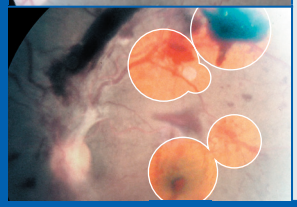		71, 75	**High risk PDR**

**See Glossary of Terms for definitions of ophthalmic terms*
**These photos are representative. They are not to scale. The contrast and colors have been adjusted for illustrative purposes.*

GLOSSARY OF TERMS

Hard exudates: small white or yellowish deposits with clear margins, which appear at the outer layers of the retina and often seem waxy, shiny, or glistening[17]

Hemorrhage: a discharge of blood from the blood vessels[18]

Intra-retinal macrovascular abnormalities (IRMA): spidery abnormal vessels that appear within the retina that are thought to be outgrowths of existing capillaries or the growth of new blood vessels[19]

Microaneurysms: Small ballooning of a section of a blood vessel wall[20]

Neovascularization: formation and growth of new blood vessels, which are often considered abnormal when observed in the retina of patients with DR[20]

Optic disc: the raised disk on the retina located at the point of entry of the optic nerve[21]

Preretinal: situated or occurring in the area in front of the retina[22]

Retina: a thin layer of light-sensitive nerves at the back of the eye that help the brain form images[7]

Soft exudates: Also referred to as cotton wool spots, they appear as white, pale yellow-white or grayish-white areas with ill-defined (feathery) edges on retina scans and which may represent damaged, swollen nerve fibers or blood flow blockages to capillaries[19]

Venous beading: an occurrence in which certain sections of the retinal vein walls lose their elasticity and expand outward, giving the length of the vein the appearance of a string of beads or sausages. A strong predictor of progression to PDR[19]

Venous loops: the formation of multiple small blood vessels near, and often occurring as a result of, the blockage of a larger vessel. A strong predictor of progression to PDR[23]

Vitreous: a gel-like substance filling most of the eye that helps it maintain its round shape[24]

REFERENCES:

1. American Optometric Association. Diabetic retinopathy. AOA Web site. https://www.aoa.org/patients-and-public/eye-and-vision-problems/glossary-of-eye-and-vision-conditions/diabetic-retinopathy. Accessed June 12, 2018. ;2. Retinal diseases/health series. American Society of Retina Specialists (ASRS) Web site. https://www.asrs.org/patients/retinal-diseases. Accessed June 12, 2018.; 3. Rosenblatt BJ, Benson WE. Diabetic retinopathy. In: Yanoff M, Duker JS, eds. Ophthalmology. 3rd ed. China: Mosby Elsevier: 2009:613-621.; 4. Brownlee M, Aiello LP, Cooper ME, Vinik AI, Nesto RW, Boulton AJM. Complications of diabetes mellitus. In: Melmed S, Polonsky KS, Larsen PR, Kronenberg HM, eds. Williams Textbook of Endocrinology. 12th ed. Philadelphia, PA: Elsevier Saunders; 2011:1462-1551.; 5. National Eye Institute. Facts about diabetic eye disease. National Institutes of Health Web site. http://nei.nih.gov/health/diabetic/retinopathy. Last Updated September 2015. Accessed June 12, 2018.; 6. Centers for Disease Control and Prevention. National Diabetes Statistics Report, 2017. Atlanta, GA: Centers for Disease Control and Prevention, U.S. Dept of Health and Human Services; 2017. ; 7. National Eye Institute. Statistics and data: diabetic retinopathy. National Institutes of Health: National Eye Institute Web site. https://nei.nih.gov/eyedata/diabetic. Accessed June 12, 2018.; 8. Woodcock A et al. The influence of diabetic retinopathy on quality of life to guide the design of a condition-specific, individualized questionnaire: the retDQoL. Patient Educ Couns. 2004; 55:365-83.; 9. Centers for Disease Control and Prevention. National diabetes fact sheet: national estimates and general information on diabetes and prediabetes in the United States, 2011. Atlanta, GA: US Department of Health and Human Services, Centers for Disease Control and Prevention, 2011.; 10. Zhang X, Saaddine JB, Chou CF, et al. Prevalence of diabetic retinopathy in the United States, 2005-2008. JAMA. 2010;304(6):649-656; 11. Yau JWY, Rogers SL, et al. Global prevalence and major risk factors of diabetic retinopathy. Diabetes Care. 2012;35(3):556-564; 12. American Diabetes Association. 10. Microvascular complications and foot care: Standards of Medical Care in Diabetes 2018. Diabetes Care 2018;41(Suppl. 1):S105–S118. 13. Mazhar K, et al. Severity of diabetic retinopathy and health-related quality of life: the Los Angeles Latino eye study. Ophthalmology. 2011;118(4): 649–655.; 14. Early Treatment Diabetic Retinopathy Study Research Group. Fundus Photographic Risk Factors for Progression of Diabetic Retinopathy: ETDRS report number 12. Ophthalmology. 1991;98(5 suppl):823-833.; 15. Early Treatment Diabetic Retinopathy Study Research Group. Early photocoagulation for diabetic retinopathy: ETDRS report number 9. Ophthalmology. 1991;98(5 suppl):766-785.; 16. University of Iowa Health Care. The COMS grading scheme: graded features – hard exudates. University of Iowa Health Care: Opthalmology and Visual Sciences Web site. http://webeye.ophth.uiowa.edu/dept/coms/grading/hard-exudates.htm. Accessed July 3, 2018.; 17. Hemorrhage. (n.d.) In Merriam-Webster's collegiate dictionary online. https://www.merriam-webster.com/dictionary/hemorrhage. Accessed July 3, 2018.; 18. Bucca B. Opthalmology. Barbara Davis Center for Diabetes University of Colorado Web site. http://www.ucdenver.edu/academics/colleges/medicalschool/centers/BarbaraDavis/Clinical/Pages/Ophthalmology.aspx. Accessed July 3, 2018.; 19. Vislesil J and Oetting T. from one medical student to another. University of Iowa Health Care: Opthalmology and Visual Sciences Web site. https://webeye.ophth.uiowa.edu/eyeforum/tutorials/diabetic-retinopathy-med-students/Classification.htm. Accessed July 3, 2018.; 20. Optic disc. (n.d.) In English Oxford dictionary online. https://en.oxforddictionaries.com/definition/optic_disc. Accessed August 27, 2018.; 21. Preretinal. (n.d.) In Merriam-Webster's collegiate dictionary online. https://www.merriam-webster.com/medical/preretinal. Accessed July 3, 2018.; 22. Bhavsar AR et al. Diabetic retinopathy. Medscape Web site. May 4, 2018. https://emedicine.medscape.com/article/1225122-overview. Accessed August 27, 2018.; 23. National Eye Institute. Facts about vitreous detachment. National Institutes of Health: National Eye Institute Web site Medscape. https://nei.nih.gov/health/vitreous/vitreous. Accessed July 3, 2018.

REGENERON
SCIENCE TO MEDICINE®

05/2019
US-OPH-14009a(1)